

# Betaine Attenuates The Expression of Vasoactive Mediators and Histological Alterations Associated with Ovarian Hyperstimulation Syndrome in Rats

Mohammad Reza Abbasi, D.V.M.<sup>1</sup>, Javad Jamshidian, Ph.D.<sup>2</sup>, Zahra Basir, Ph.D.<sup>3\*</sup> , Mohammad Reza Tabandeh, Ph.D.<sup>4, 5</sup>

1. Faculty of Veterinary Medicine, Shahid Chamran University of Ahvaz, Ahvaz, Iran
2. Department of Pharmacology, Faculty of Veterinary Medicine, Shahid Chamran University of Ahvaz, Ahvaz, Iran
3. Department of Basic Sciences, Faculty of Veterinary Medicine, Shahid Chamran University of Ahvaz, Ahvaz, Iran
4. Department of Biochemistry and Molecular Biology, Faculty of Veterinary Medicine, Shahid Chamran University of Ahvaz, Ahvaz, Iran
5. Stem Cells and Transgenic Technology Research Center, Shahid Chamran University of Ahvaz, Ahvaz, Iran

## Abstract

**Objective:** Ovarian hyperstimulation syndrome (OHSS) is one female reproductive disorder that can occur after administration of injectable hormonal drugs to stimulate ovulation. Betaine (BET) is an intracellular biomolecule with anti-inflammatory and tissue protective effects. There is no information about its effects in an experimental model of OHSS. The current study aims to investigate the possible effects of BET on abnormal expressions of vasoconstrictor proteins and ovarian histological changes in an experimental OHSS rat model.

**Materials and Methods:** In this experimental study, 30 adult female rats (two months old) were randomly divided into six groups (n=5 per group): i. Control, ii. OHSS [10 IU sc equine chorionic gonadotropin (eCG) for 4 days followed by 30 IU sc human chorionic gonadotropin (hCG) on the fifth day], iii. OHSS+BET (200 mg/kg/day, orally for seven days), iv. OHSS+Cabergoline (CAB, 100 mg/kg/day, orally for six days), v. BET, and vi. CAB. Expression levels of vascular endothelial growth factor (VEGF), cyclooxygenase-2 (COX-2), and blood levels of oestradiol (E2) and progesterone (P4) were measured at the end of the experiment. The ovaries were studied for histomorphological changes.

**Results:** Induction of OHSS altered tissue histology, including an increase in the number of corpora lutea and atretic follicles, and decreased the number of follicular reserves. In this group, we observed increased expressions of the VEGF and COX-2 proteins, and increased serum E2 and P4 levels. Administration of CAB and BET significantly attenuated all molecular and histological alterations observed in the OHSS animals.

**Conclusion:** Our findings, for first time, indicate the beneficial effects of BET to reduce OHSS complications in patients by reducing the expressions of vasoactive proteins and improving changes to the ovarian tissues. The findings are similar to CAB and can be a new avenue for future research on BET.

**Keywords:** Angiogenesis, Betaine, Cabergoline, Ovarian Histomorphology, Ovarian Hyperstimulation Syndrome

**Citation:** Abbasi MR, Jamshidian J, Basir Z, Tabandeh MR. Betaine attenuates the expression of vasoactive mediators and histological alterations associated with ovarian hyperstimulation syndrome in rats. *Cell J.* 2024; 26(4): 259-266. doi: 10.22074/CELLJ.2024.2022353.1504

This open-access article has been published under the terms of the Creative Commons Attribution Non-Commercial 3.0 (CC BY-NC 3.0).

## Introduction

The ovaries are paired structures that contain immature ovum that can develop into mature eggs and acquire the ability to fertilise (1). Approximately 10% of patients who undergo *in vitro* fertilization (IVF) cycles, embryo transfer, stimulation of ovulation, or intrauterine insemination develop ovarian hyperstimulation syndrome (OHSS) (2-4). Clinical manifestations of this complication include extensive accumulation of fluid in the extracellular spaces and condensation of blood due to leakage of fluid from the arteries, and this can be associated in advanced-stage renal impairment, hypovolemic shock, thromboembolism, and respiratory distress (5, 6). This syndrome is caused by increased expression and secretion of vascular endothelial

growth factors (VEGF) and cyclooxygenase 2 (COX-2) (5, 7-10). Therefore, the use of compounds that inhibit VEGF secretion can play an effective role in the prevention of OHSS (8, 11, 12) Cabergoline (CAB), a low-dose dopamine receptor (Dp-R2), inhibits vascular permeability and can be used as a prophylactic treatment for OHSS syndrome (12-16). Trimethylglycine, also known as betaine (BET), is synthesised in the inner mitochondrial membrane and functions as an osmoprotectant and methyl group donor in various cellular pathways in mammals (17). BET may have a functional role in female reproductive health and fertility. Recent findings indicate that BET can inhibit retinal vascularisation by suppression of VEGF and COX-2 expressions (17, 18). Currently, the effects of BET on

Received: 12/December/2022, Revised: 27/November/2023, Accepted: 23/December/2023

\*Corresponding Address: P.O.Box: 6135783151, Department of Basic Sciences, Faculty of Veterinary Medicine, Shahid Chamran University of Ahvaz, Ahvaz, Iran

Email: z.basir@scu.ac.ir



Royan Institute  
Cell Journal (Yakhteh)

the molecular and histological changes observed in animal models of OHSS are unknown. The current study aims to investigate the effects of BET on the expressions of vasoactive proteins and histological changes induced by experimental OHSS in rat ovaries and compare its effects with CAB, an effective drug used to manage OHSS complications.

## Materials and Methods

### Animals and treatment assignments

A total of 30 female, two-month-old unmated Wistar rats (weights: 150-200 g) were acquired from the Animal House of the Faculty of Veterinary Medicine, Shahid Chamran University, Ahvaz, Iran. The animals were kept under a constant room temperature of  $20 \pm 11^\circ\text{C}$ , humidity of 40-50%, and a 12-hour light/dark cycle. The rats were fed pelleted food (Pars, Tehran, Iran) for one week to allow them to adjust to their new environment.

The animals were weighed and randomly divided into six groups ( $n=5$  per group), as follows: group I (control) rats were given 0.9% normal saline (0.1 ml/kg, sc) for five days. From day 0 of the assessment, the rats received a daily oral dose of 1 mg/kg normal saline for ten days. Group II (OHSS) rats received sc injections of equine chorionic gonadotropin (eCG, IBSA, Montagnola, Switzerland) dissolved in 0.1 ml of 0.9% normal saline (10 IU) for 4 days. On the fifth day, they received an sc injection of 30 IU human chorionic gonadotropin (hCG; Darou Pakhsh, Tehran, Iran) (19). Group III (OHSS+BET) OHSS rats were given 200 mg of oral BET (betaine anhydrous, Sigma, USA) two days before the eCG administration, for seven days. Group IV (OHSS+CAB) OHSS rats, from the first day of the test, were given 100  $\mu\text{g}/\text{kg}/\text{d}$  oral CAB (Shahredaru, Iran) dissolved in 5% glucosaline for six days (19). Group V (BET) rats were given 200 mg of oral BET for seven days. Group VI (CAB) rats received 100  $\mu\text{g}/\text{kg}$ , oral

CAB dissolved in 5% glucosamine for five days.

As described previously, OHSS induction was confirmed by an increase in the delta value of body weight and elevation of the oestradiol (E2) and progesterone (P4) hormones.

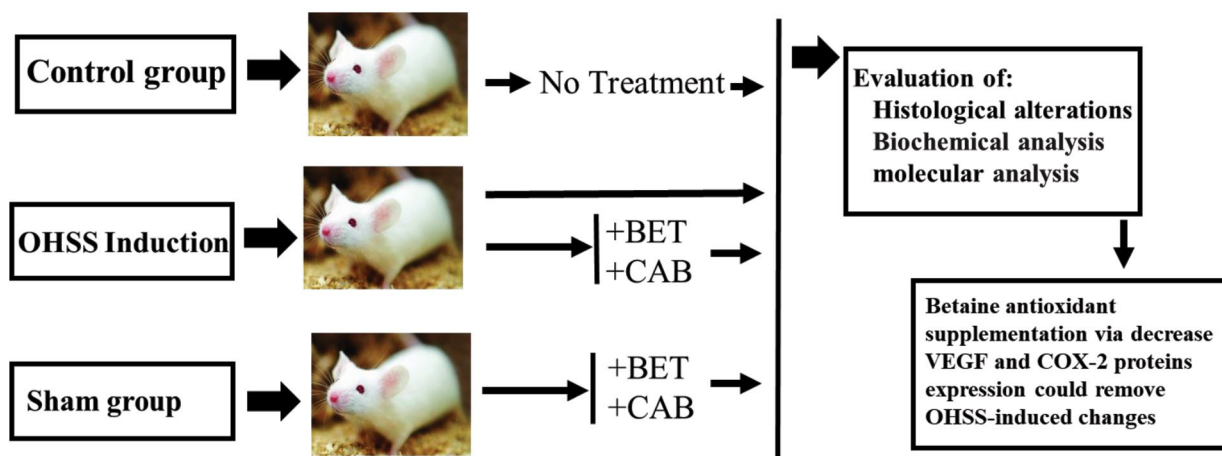
This research was approved by the Ethics Committee of Shahid Chamran University, Ahvaz, Iran (EE/99.3.02.38347/scu.ac.ir). Figure 1 presents the research design.

At the end of trial period, the rats in all groups were weighed and euthanised with ketamine and xylazine (100 mg/kg+10 mg/kg). Serum samples were taken by heart puncture and stored at  $-20^\circ\text{C}$  until hormone analysis. Both ovaries of each rat were removed and weighed. One ovary was fixed in 10% formalin buffer for the histological analyses, and other ovary was stored at  $-70^\circ\text{C}$  for molecular analysis.

### Histological evaluations

The tissues were cut into 5  $\mu\text{m}$  sections and stained with haematoxylin and eosin (H&E, Merck, Germany) (20). Histomorphometric studies were performed using a light microscope (Olympus BH-2, Japan) equipped with a Dino-Eye lens (AM7023, Taiwan) and DinoCapture 2.0 imaging software at  $200\times$  magnification.

Ovarian histological changes to the ovarian diameter (mm), the follicular reserve count, number and diameter of the corpora lutea ( $\mu\text{m}$ ), number of atretic follicles and vascular reserve were evaluated, in addition to assessments of hyperaemia, haemorrhage, mononuclear cell infiltration, and interstitial tissue oedema. Counts were performed in 10 microscopic fields of view from each ovary and given a score between 0 and 3 for the ovarian tissue changes: 0 (unchanged), 1 (lowest), 2 (lowest moderate), and 3 (most change) (21).



**Fig.1:** Schematic diagram of the treatment protocol. BET; Betaine, CAB; Cabergoline, VEGF; Vascular endothelial growth factor, COX-2; Cyclooxygenase-2, and OHSS; Ovarian hyperstimulation syndrome.

## Biochemical analyses

The serum levels of P4 (ng/ml) and E2 (pg/ml) were measured by an ELISA Kit (Alpine, USA) according to the manufacturer's instructions.

## Evaluation of vascular endothelial growth factor and cyclooxygenase 2-expressions

The protein expressions of VEGF and COX-2 in the ovaries of the experimental animals were determined by Western blot analysis. The frozen tissues were lysed in 200  $\mu$ l lysis buffer (50 mM tris-HCl, 150 mM NaCl, 0.1% Triton X-100, 1 mM NaF) supplied with protease inhibitor cocktails (Sigma-Aldrich, MO, USA) for 30 minutes on ice. Primary antibody VEGF (Abcam, Cambridge, UK, Art No: ab46154) and COX-2 (Abcam, Cambridge, UK, Art No: ab179800) were incubated with an appropriate secondary antibody [goat anti-rabbit IgG, Abcam: ab133470 (618)].  $\beta$ 2-microglobulin (B2M, Abcam, Cambridge, UK, Art No: ab214769) was used as the calibrator protein. ImageJ software (National Institutes of Health, Bethesda, MD, USA) was used to analyse the optical density of the protein bands. A control group was the calibrator group (21).

## Statistical analysis

Data were analysed by Graphpad Prism software (version 5.0.4, Graphpad Software, Inc., San Diego, CA, USA). Data are presented as mean  $\pm$  SEM. Bilateral ANOVA was performed and Tukey's post hoc test was used for multiple comparisons. Statistically significance differences between the different experimental groups were determined, as follows: \*,  $P < 0.05$ , \*\*,  $P < 0.01$ , \*\*\*,  $P < 0.001$ , and \*\*\*\*,  $P < 0.0001$ .

## Results

### Analysis of body weight changes

Table S1 (See Supplementary Online Information at [www.celljournal.org](http://www.celljournal.org)) displays the weight changes in the

groups. Statistical analysis revealed that the delta value of body weight (final weight-initial weight) showed a significant increase in the OHSS group compared to the control group. The delta body weight in the OHSS group treated with CAB showed a significant decrease compared to the OHSS group treated with BET ( $P < 0.01$ ). The weight changes in the BET and CAB groups were similar to the control group.

### Analysis of hormones in serum

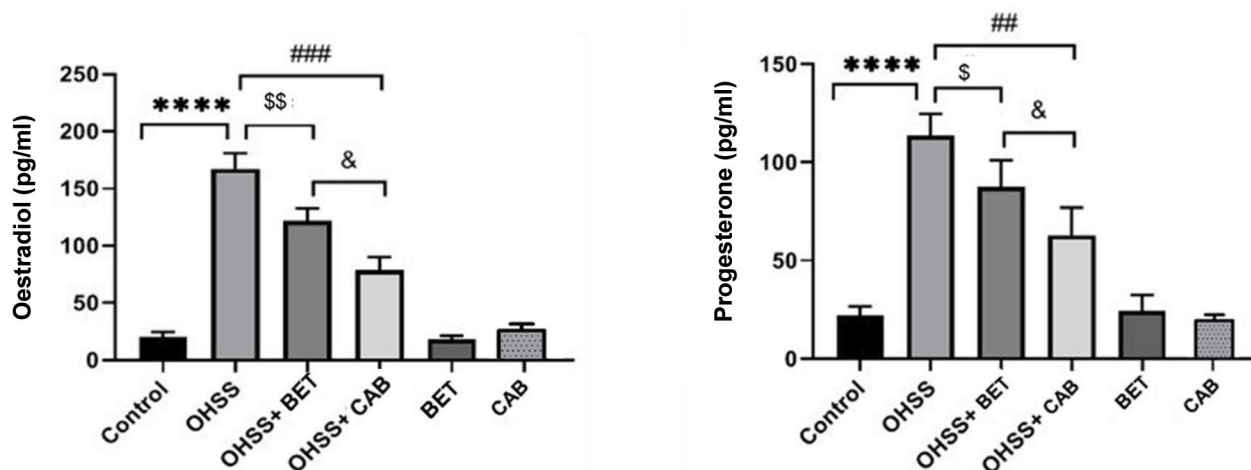
Figure 2 illustrates the serum concentrations of E2 and P4 in the study groups. There was a significant increase in serum E2 and P4 levels in the OHSS group compared with the control group ( $P < 0.0001$ ). The CAB treated group had a decrease in E2 and P4 levels compared to the BET treated group ( $P > 0.05$ ).

### Analysis of protein expressions in the ovaries

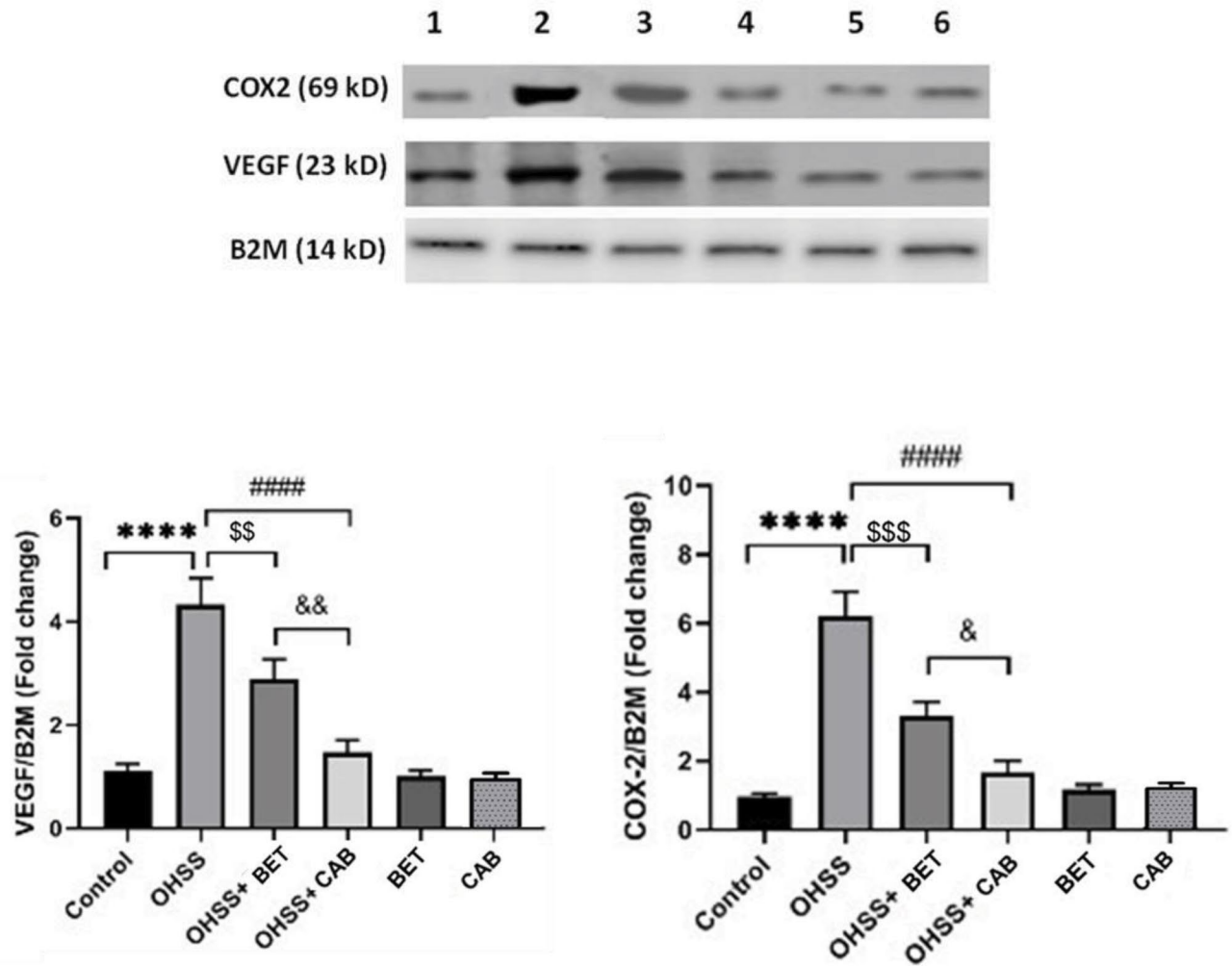
Figure 3 shows the VEGF and COX-2 protein expressions in the ovarian tissues for all of the study groups. Our results showed a significant increase in VEGF and COX-2 protein expression in the OHSS group compared with the control group ( $P < 0.0001$ ). The OHSS+CAB group showed a significant decrease ( $P < 0.0001$ ) in VEGF and COX-2 expressions when compared between the two treatment groups. The OHSS+BET group also showed a significant decrease in VEGF ( $P < 0.01$ ) and COX-2 ( $P < 0.001$ ) expressions.

### Analysis of ovarian morphometry

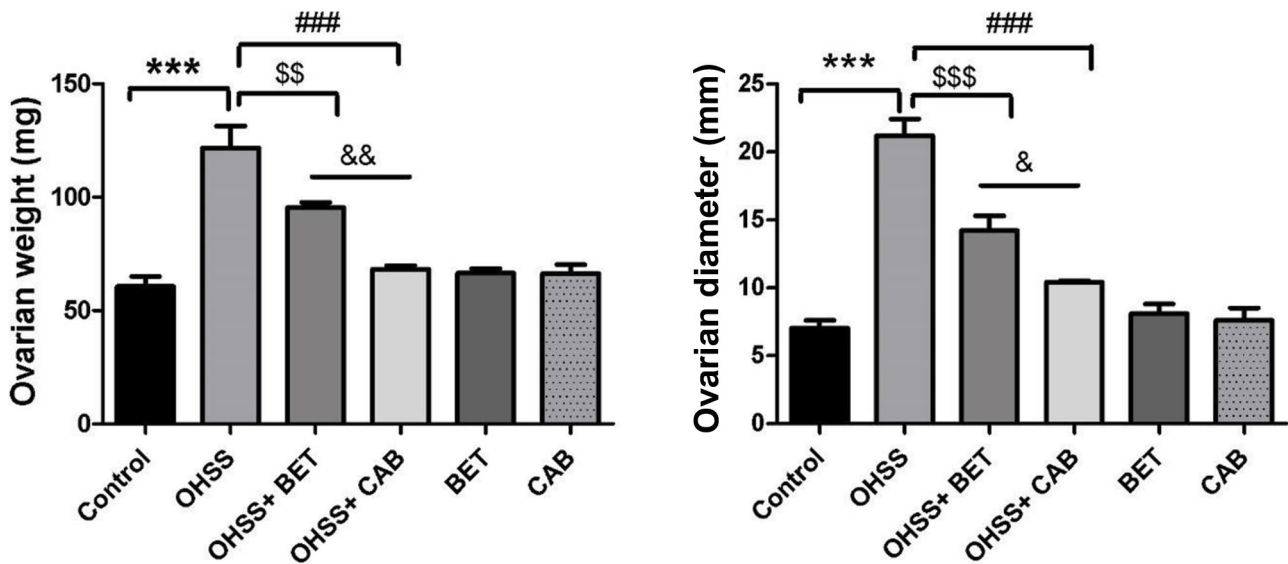
Our results revealed that ovarian weight and diameter significantly increased in the OHSS group compared to the control group ( $P < 0.0001$ ). The ovarian diameters after treatment with BET ( $P < 0.001$ ) and CAB ( $P < 0.001$ ) were significantly lower compared to the OHSS group. Our results indicated that the ovarian weight was lower in the BET-treated group compared with the CAB-treated group ( $P < 0.01$ ). Figure 4 shows the results of ovarian anatomical analysis.



**Fig.2:** E2 and P4 serum levels in the study groups. E2; Oestradiol, P4; Progesterone, OHSS; Ovarian hyperstimulation syndrome, BET; Betaine, CAB; Cabergoline, \*\*\*\*,  $P < 0.0001$ , ##,  $P < 0.01$ , ###,  $P < 0.001$ , &,  $P < 0.05$ , \$,  $P < 0.05$ , and \$\$,  $P < 0.01$ .



**Fig.3:** Quantitative results of VEGF and COX-2 protein expressions in ovarian tissues of the studied groups. VEGF; Vascular endothelial growth factor, COX-2; Cyclooxygenase-2, OHSS; Ovarian hyperstimulation syndrome, BET; Betaine, CAB; Cabergoline, \*\*\*, P<0.0001, ####, P<0.0001, &, P<0.05, &&, P<0.01, \$\$, P<0.01, and \$\$\$, P<0.001.



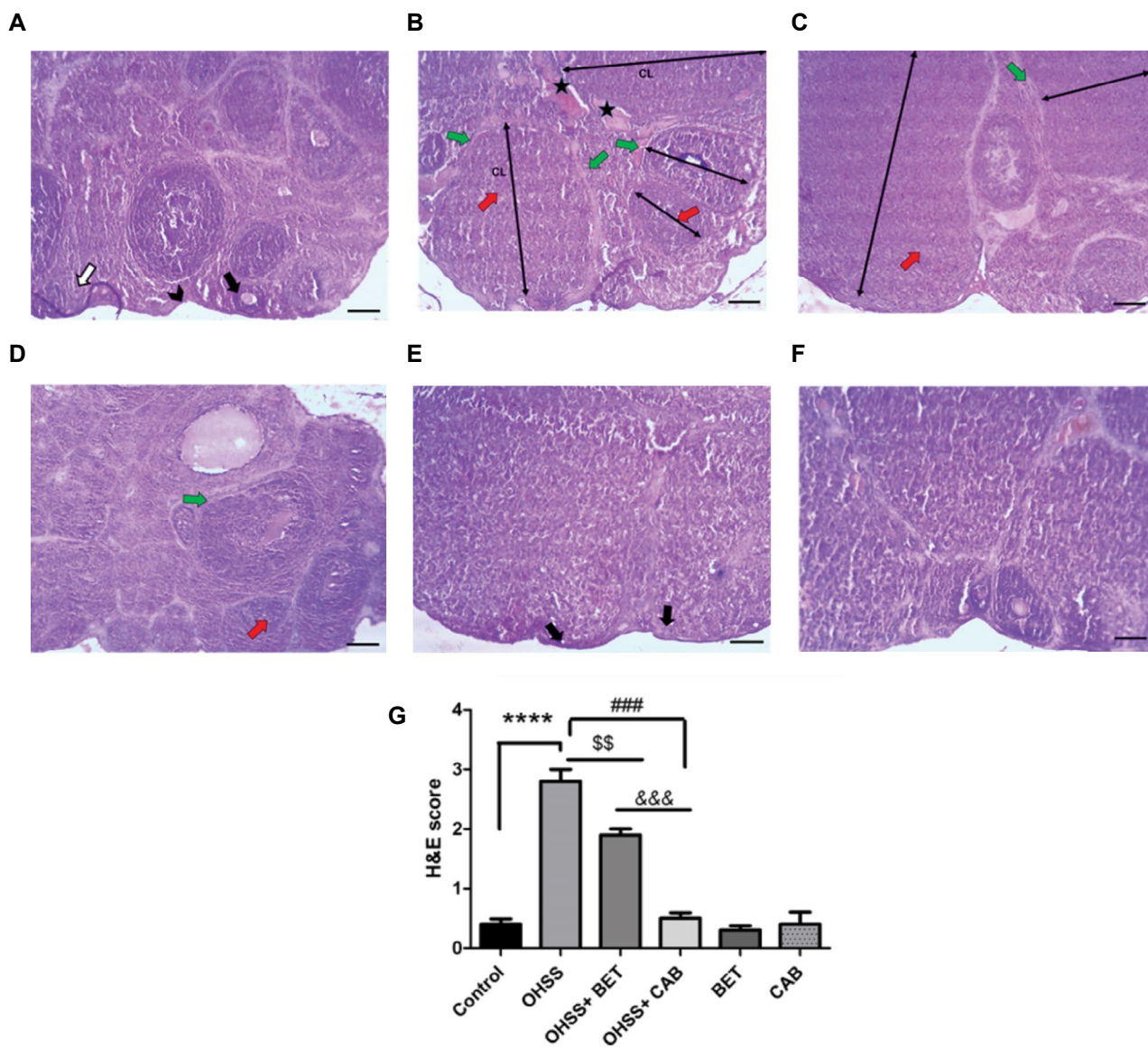
**Fig.4:** Comparison of the protective effect of BET and CAB on morphometrical changes in the study groups. OHSS; Ovarian hyperstimulation syndrome, BET; Betaine, CAB; Cabergoline, \*\*\*, P <0.001, ###, P <0.001, &, P <0.05, &&, P <0.01, \$\$, P <0.01, and \$\$\$, P <0.001.

### Analysis of histological parameters

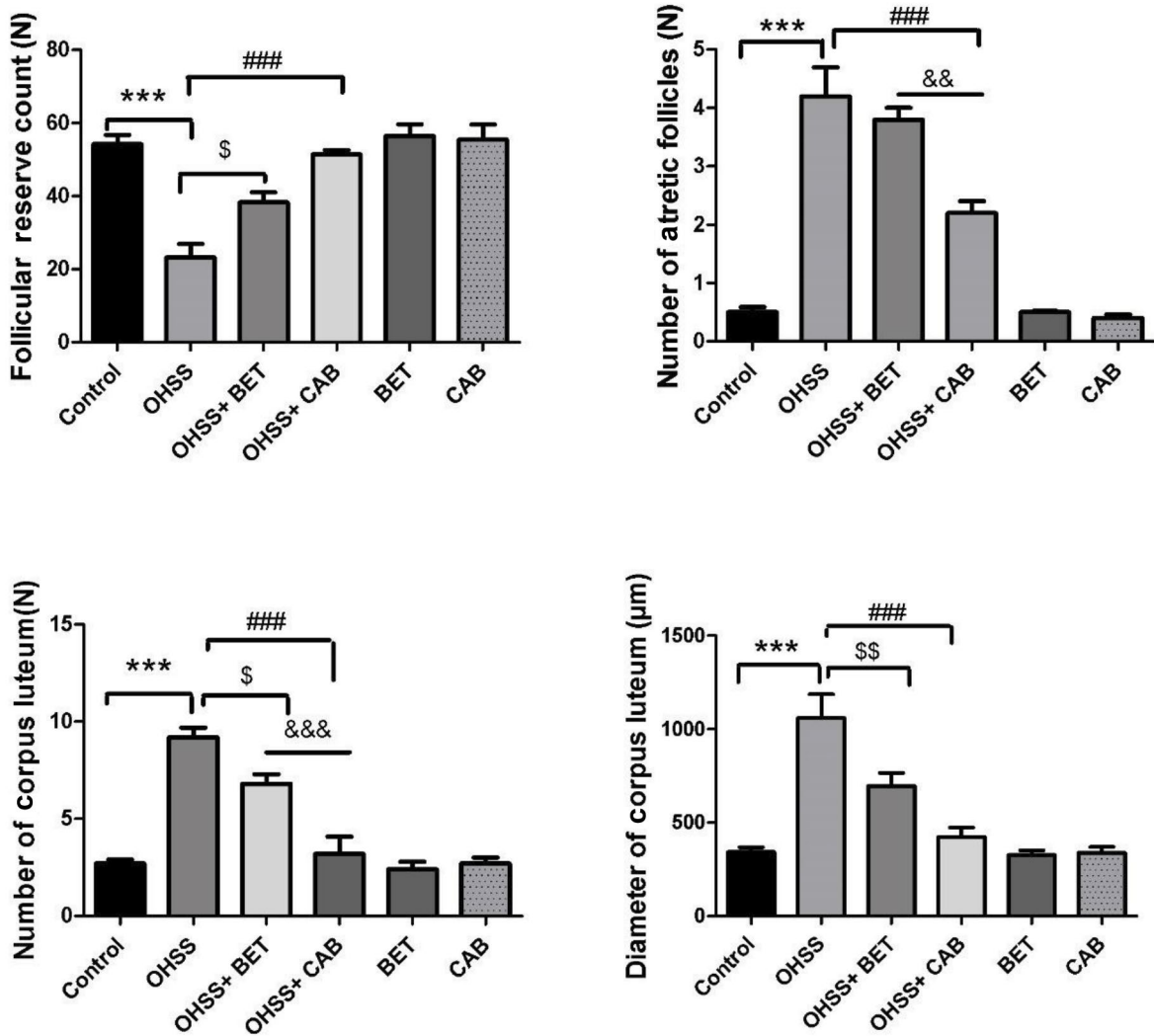
Histological analysis revealed that the control group showed a normal ovary with normal follicles (Fig.5A). OHSS induction caused the tunica albuginea tissue around the ovary to become thinner. In the OHSS group, there was an increase in the atretic follicles, and the number and diameter of corpora lutea in the ovarian cortex, and a decrease in the number of follicular reserves. Also, in the OHSS group, the ovarian stroma and lutein cells of the corpus luteum had numerous blood vessels, and the nuclei of the lutein cells of the corpus luteum were dense and pyknotic. The medullary part of the ovary of the OHSS group had hyaline casts and numerous dilated blood

vessels. Oedema, hyperaemia, and haemorrhage were also observed (Fig.5B). These changes were reduced after treatment with CAB or BET compared to the OHSS group (Fig.5C, D). Ovaries in the BET and CAB groups showed a tissue structure similar to the control group (Fig.5E, F).

The results of the histomorphometric analysis of the ovaries are presented in Figure 6. The numbers and diameter of the corpora lutea and numbers of the atretic follicle in the OHSS group were higher, and the follicular reserve count was lower than the control group ( $P<0.001$ ). Treatment with CAB or BET significantly reduced all histomorphometric changes observed in the OHSS group.



**Fig.5:** These figures show the histological images of ovaries in the study groups (H&E stain, 100× magnification, scale bar: 50 µm). **A.** The control group, **B.** OHSS, **C.** OHSS+BET, **D.** OHSS+CAB, **E.** BET, and **F.** CAB groups. Superficial lining tissue of the ovary (arrowhead), primordial follicle (white arrow), primary follicle (black arrow), thickening of the connective tissue wall around the follicle (green arrow), hyperaemia in the corpus luteum (red arrow), and hyperaemia in the ovarian stroma (star) are shown. **G.** Histomorphometric changes. Data are presented as mean ± SEM from 10 sections per rat and five animals per group. H&E; Haematoxylin and eosin, CL; Corpus luteum, OHSS; Ovarian hyperstimulation syndrome, BET; Betaine, CAB; Cabergoline, \*\*\*\*;  $P<0.0001$ , ###;  $P<0.001$ , &&&  $P<0.001$ , and \$\$\$  $P<0.01$ .



**Fig.6:** Comparison of the protective effects of BET and CAB on tissue changes in the study groups. OHSS; Ovarian hyperstimulation syndrome, BET; Betaine, CAB; Cabergoline, \*\*\*, P<0.001, ###, P<0.001, &&& P<0.001, \$, P<0.05, and \$\$, P<0.01.

### Discussion

Increasing access to *in vitro* fertilisation has assisted numerous women worldwide who otherwise would not be able to achieve a normal pregnancy. However, an increased risk of OHSS is a potential side effect of this treatment (4, 22-25). OHSS syndrome increases the expression and secretion of VEGF, and the expression of VEGF receptors from stimulated ovaries; this, in turn, creates increased vascular permeability and ovarian disorders (5, 9). Women with OHSS have evidence of significantly increased body weight, and ovarian weight and diameter (4, 7, 26, 27). The present study showed a significant increase in delta values of body weight, and ovarian weight and diameter in the OHSS group. We observed that BET and CAB treatment attenuated the elevated levels of body weight, and ovarian weight and diameter. Numerous researchers have previously shown that CAB can be used to attenuate OHSS clinical symptoms (12, 13, 16, 19, 25, 28, 29). According to our findings, induction of OHSS resulted in several histological changes in the ovarian tissue,

which included increased numbers of atretic follicles, increased diameter and number of the corpora lutea, decreased follicular reserve count, and increased numbers of blood vessels in the corpora lutea and ovarian stroma. These changes have been previously reported by many researchers and support our findings (30, 31). The results of the current study showed that administration of CAB or BET significantly attenuated the histological changes induced by OHSS, which supported the results of previous researches. We observed significantly increased VEGF and COX-2 protein expressions in ovaries of the OHSS group compared to the control group (25, 32). Treatment of OHSS group with CAB or BET significantly downregulated the increased VEGF and COX-2 protein expressions. These findings agreed with previous studies (19, 25, 33) that reported significant increases in serum levels of E2 and P4 in OHSS animals. Various studies have shown that CAB administration to an experimental OHSS model reduced the increased levels of E2 and P4 (7, 12, 13, 19). Although CAB administration reduces OHSS complications and

is a definitive drug to prevent OHSS, it does have side effects (headache, peripheral oedema, shortness of breath, bleeding from the nose), contraindications (breastfeeding, cardiovascular problems, pulmonary and respiratory problems, high blood pressure), and drug interactions (vascular contraceptives, oral contraceptive pills, blood pressure-lowering drugs) (11, 14).

BET is a natural compound that is released in biological systems for protection against environmental osmotic and oxidative stressors (34, 35). BET appears to decrease VEGF protein expression and suppress new vascularisation in the ovaries of rats (17, 36-38). To the best of our knowledge, there are no reported results that show the benefits of treatment with BET compared with CAB in reducing the side effects of OHSS. Our results indicate that BET reduced VEGF and COX-2 protein expressions along with attenuation of vascularisation in cortical tissue and ovarian medulla of an OHSS animal model. In the BET-treated group, the increased body weight, and microscopic and macroscopic ovarian changes from OHSS were reduced, and this was similar to CAB, as an efficient drug for attenuation of OHSS complications. In comparison between the two treated groups, BET group had evidence of increased improvements in the effects on all molecular and histological changes compared with the CAB group.

## Conclusion

Our results show a wealth of evidence to support the effectiveness of BET in reducing OHSS complications. We noted that BET administration reduced the vasodilator protein (VEGF and COX-2) expressions, improved ovarian steroidogenesis, and mitigated the histological alterations associated with OHSS. Further research is needed to optimise BET dosages and administration route. Additionally, ongoing monitoring and long-term studies are crucial to ensure the safety and efficacy of this treatment in OHSS patients.

## Acknowledgements

The results presented in this paper were part of a DVM graduate student thesis. This work was funded by a grant from Shahid Chamran University of Ahvaz Research Council (GN: SCU.VB1401.103). The authors declare that there is no conflict of interest.

## Authors' Contributions

Z.B.; Is the guarantor of this work, Study design, Data analysis, Wrote the original draft, and Full access to the study data. M.R.A.; Experimental work and Study design. J.J.; Assisted with dosage design, Study design, and Data collection. M.R.T.; Performed the biochemistry, Molecular studies, Study design, and Edited the final manuscript. All authors read and approved the final manuscript.

## References

- Eurell JA, Frappier BL. Dellmann's textbook of veterinary histology. 6<sup>th</sup> edition. John Wiley & Sons; Wiley-Blackwell: 2013.
- Shpakov AO. Improvement effect of metformin on female and male reproduction in endocrine pathologies and its mechanisms. *Pharmaceuticals (Basel)*. 2021; 14(1): 42.
- Petrenko AP, Castelo-Branco C, Marshalov DV, Kuligin AV, Shifman EM, Nesnova ES. Assessing the usefulness of severity markers in women with ovarian hyperstimulation syndrome. *Reprod Sci*. 2021; 28(4): 1041-1048.
- Tso LO, Leis L, Glina CG, Busso CE, Romano RS, Busso NE, et al. Does the controlled ovarian stimulation increase the weight of women undergoing IVF treatment? *Eur J Obstet Gynecol Reprod Biol*. 2021; 263: 205-209.
- Li Y, Fang L, Zhang R, Wang S, Li Y, Yan Y, et al. Melatonin stimulates VEGF expression in human granulosa-lutein cells: a potential mechanism for the pathogenesis of ovarian hyperstimulation syndrome. *Mol Cell Endocrinol*. 2020; 518: 110981.
- Vidal A, Wachter C, Kohl Schwartz A, Dhakal C. A rare presentation of isolated right-sided pleural effusion in the context of ovarian hyperstimulation syndrome: a case report. *Case Rep Womens Health*. 2021; 32: e00347.
- Kasap E, Turan GA, Eskicioğlu F, Cengiz H, Gur EB, Sivriköz ON, et al. Comparison between resveratrol and cabergoline in preventing ovarian hyperstimulation syndrome in a rat model. *Gynecol Endocrinol*. 2016; 32(8): 634-640.
- Ferrero H, García-Pascual CM, Pellicer N, Simón C, Pellicer A, Gómez R. Dopamine agonist inhibits vascular endothelial growth factor protein production and secretion in granulosa cells. *Reprod Biol Endocrinol*. 2015; 13: 104.
- Hulde N, Rogenhofer N, Brettner F, Eckert NC, Fetz I, Buchheim JI, et al. Effects of controlled ovarian stimulation on vascular barrier and endothelial glycocalyx: a pilot study. *J Assist Reprod Genet*. 2021; 38(9): 2273-2282.
- Mohamed MO, Adam EA, Abdlla BM, Abdelghani S, Eltayeb LB. Vascular endothelial growth factor (VEGF) as biological markers expressed in ovarian cancer using immuno-histochemical technique. *J Med Sci*. 2021; 25(112): 1311-1317.
- Fouda UM, Elshaer HS, Youssef GG, Hanafy A, Mehrem WM, Youssef MA, et al. Cabergoline versus calcium infusion in the prevention of ovarian hyperstimulation syndrome: a randomised controlled study. *J Obstet Gynaecol*. 2022; 42(1): 122-126.
- Tang H, Mourad SM, Wang A, Zhai SD, Hart RJ. Dopamine agonists for preventing ovarian hyperstimulation syndrome. *Cochrane Database Syst Rev*. 2021; 4(4): CD008605.
- Liu L, Wang X, Meng T, Jyu J, Lyu F, Zhang X. The influence of cabergoline and coasting in prevention of the ovarian hyperstimulation syndrome in patients undergoing IVF/ICSI-ET treatment: a systematic review and meta-analysis. *Adv Reprod Sci*. 2020; 8(2): 143.
- Şanlı C, Atılcan R, Kuloğlu T, Pala Ş, Aydın Türk B, Keser HB, et al. Transient receptor potential melastatin 2 ion channel activity in ovarian hyperstimulation syndrome physiopathology. *Turk J Med Sci*. 2021; 51(2): 787-795.
- Rubenfeld ES, Dahan MH. Does the timing of cabergoline administration impact rates of ovarian hyperstimulation syndrome? *Obstet Gynecol Sci*. 2021; 64(4): 345-352.
- Oishi S, Mekaru K, Nakamura R, Miyagi M, Akamine K, Heshiki C, et al. Two cases of polycystic ovary syndrome with onset of severe ovarian hyperstimulation syndrome following controlled ovarian stimulation with aromatase inhibitors for fertility preservation before breast cancer treatment. *Taiwan J Obstet Gynecol*. 2021; 60(5): 931-934.
- Samie KA, Tabandeh MR, Afrough M. Betaine ameliorates impaired steroidogenesis and apoptosis in mice granulosa cells induced by high glucose concentration. *Syst Biol Reprod Med*. 2020; 66(6): 400-409.
- Zhao G, He F, Wu C, Li P, Li N, Deng J, et al. Betaine in inflammation: mechanistic aspects and applications. *Front Immunol*. 2018; 9: 1070.
- Engin-Ustun Y, Yilmaz S, Timur H, Ustun Y, Moraloglu O, Deveer R, et al. Comparison of bevacizumab and cabergoline in the treatment of ovarian hyperstimulation syndrome in a rat model. *Gynecol Endocrinol*. 2013; 29(9): 851-854.
- Fatemi I, Khalili H, Mehrzadi S, Basir Z, Malayeri A, Goudarzi M. Mechanisms involved in the possible protective effect of chrysin against sodium arsenite-induced liver toxicity in rats. *Life Sci*. 2021; 267: 118965.
- Darabi Z, Basir Z, Tabandeh MR, Ghotbeddin Z. Coenzyme Q10 improves ovarian histology and attenuates the expression of angiogenesis-associated proteins in the ovary of rats with experimen-

- tal hyperstimulation syndrome. *Iran J Basic Med Sci.* 2022; 25(8): 989-996.
22. Shields R, Vollenhoven B, Ahuja K, Talmor A. Ovarian hyperstimulation syndrome: a case control study investigating risk factors. *Aust N Z J Obstet Gynaecol.* 2016; 56(6): 624-627.
  23. Barua S, Hng TM, Smith H, Bradford J, McLean M. Ovulatory disorders are an independent risk factor for pregnancy complications in women receiving assisted reproduction treatments. *Aust N Z J Obstet Gynaecol.* 2017; 57(3): 286-293.
  24. Zheng X, Guo W, Zeng L, Zheng D, Yang S, Xu Y, et al. In vitro maturation without gonadotropins versus in vitro fertilization with hyperstimulation in women with polycystic ovary syndrome: a non-inferiority randomized controlled trial. *Hum Reprod.* 2022; 37(2): 242-253.
  25. Yanagihara Y, Tanaka A, Nagayoshi M, Tanaka I, Shinohara R, Fukushima F, et al. A modified GnRH antagonist method in combination with letrozole, cabergoline, and GnRH antagonist for PCOS: Safe and effective ovarian stimulation to treat PCOS and prevent OHSS. *Reprod Med Biol.* 2021; 21(1): e12429.
  26. Višňová H, Papaleo E, Martin FS, Koziol K, Klein BM, Mannaerts B. Clinical outcomes of potential high responders after individualized FSH dosing based on anti-Müllerian hormone and body weight. *Reprod Biomed Online.* 2021; 43(6): 1019-1026.
  27. Dirik D, Kömüro-lu AU. The effect of infliximab on oxidative stress in ovarian tissue of the rat with ovarian hyperstimulation syndrome. *East J Med.* 2021; 26(3): 475-480.
  28. Soares SR. Etiology of OHSS and use of dopamine agonists. *Fertil Steril.* 2012; 97(3): 517-522.
  29. Hortu I, Karadadas E, Ozceltik G, Tavmergen E, Tavmergen Goker EN, Yigitturk G, et al. Oxytocin and cabergoline alleviate ovarian hyperstimulation syndrome (OHSS) by suppressing vascular endothelial growth factor (VEGF) in an experimental model. *Arch Gynecol Obstet.* 2021; 303(4): 1099-1108.
  30. Pala Ş, Atilgan R, Ozkan ZS, Kavak SB, Ilhan N, Akpolat N, et al. Effect of varying doses of tamoxifen on ovarian histopathology, serum VEGF, and endothelin 1 levels in ovarian hyperstimulation syndrome: an experimental study. *Drug Des Devel Ther.* 2015; 9: 1761-1766.
  31. Karabulut S, Korkmaz O, Erdem Altun C, Keskin I. A histopathological evaluation of ovarian hyperstimulation syndrome on reproductive and vital organs and the role of the VEGF-PKA pathway in a mouse model. *Cells Tissues Organs.* 2021; 210(3): 218-238.
  32. Zimmerman L, Willson S, Setton R, Schattman G. Ovarian stimulation for fertility preservation (different protocols). In: Grynberg M, Patrizio P, editors. *Female and male fertility preservation.* Switzerland: Springer, Cham; 2022; 119-129.
  33. Hong YH, Kim SK, Lee JR, Jee BC, Suh CS. Clinical efficacy of dual trigger with human chorionic gonadotropin and a gonadotropin-releasing hormone agonist for women undergoing fertility preservation. *Reprod Med Biol.* 2022; 21(1): e12440.
  34. Hafez EM, Gawayed SM, Nehela Y, Sakran RM, Rady AMS, Awadalla A, et al. Incorporated biochar-based soil amendment and exogenous glycine betaine foliar application ameliorate rice (*Oryza sativa* L.) tolerance and resilience to osmotic stress. *Plants (Basel).* 2021; 10(9): 1930.
  35. Egbuniwe IC, Uchendu CN, Obidike IR. Ameliorative effects of betaine and ascorbic acid on endocrine and erythrocytic parameters of sexually-maturing female Japanese quails during the dry season. *J Therm Biol.* 2021; 96: 102812.
  36. Taghvaei S, Sabouni F, Minucmehr Z, Taghvaei A. Identification of novel anti-cancer agents, applying in silico method for SENP1 protease inhibition. *J Biomol Struct Dyn.* 2022; 40(14): 6228-6242.
  37. Wu Y, Jennings NB, Sun Y, Dasari SK, Bayraktar E, Corvigno S, et al. Targeting CCR2<sup>+</sup> macrophages with BET inhibitor overcomes adaptive resistance to anti-VEGF therapy in ovarian cancer. *J Cancer Res Clin Oncol.* 2022; 148(4): 803-821.
  38. Brito DCC, Domingues SFS, Rodrigues APR, Silva LM, Alves KA, Wu X, et al. Betaine-loaded CaCO<sub>3</sub> microparticles improve survival of vitrified feline preantral follicles through higher mitochondrial activity and decreased reactive oxygen species. *Reprod Fertil Dev.* 2020; 32(5): 531-537.